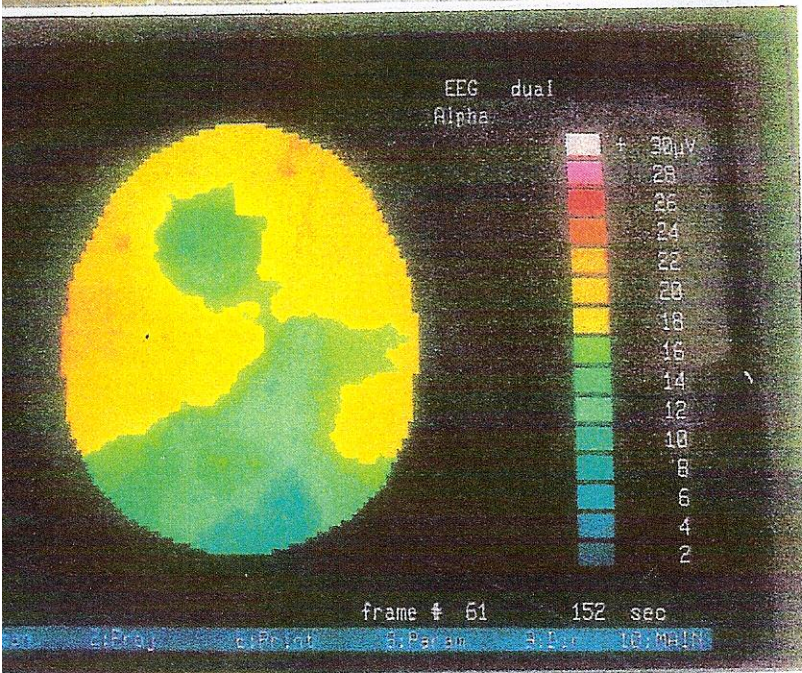
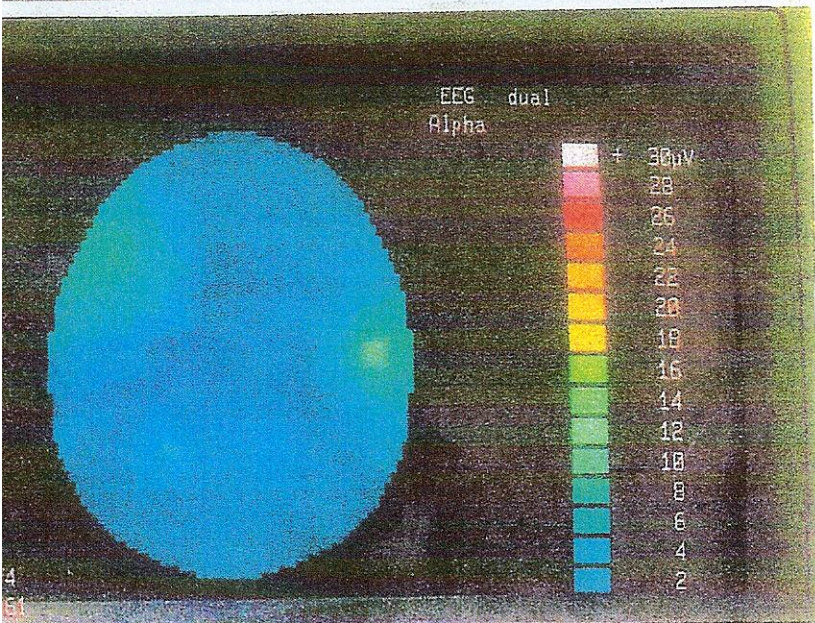




Patient connected to the Neuro-Science Brain Imager and ear clips on the ear lobes connected to the Electro-Acuscope (not in picture).



Brain map of a normal resting awake patient before Electro-Acuscope/ Electro-Sleep procedure.



Brain map of the above patient immediately after 10 mins. of Electro-Sleep with the Electro-Acuscope instrument. The patient was connected to the instrument with wires and clips to the ear lobes.

There had been no changes in the environment or in perception of the patient.

Patient was awake and alert and was not told what to expect or that there even would be a treatment.

Patient reported feeling very relaxed at the end of the treatment.